

# Depth of Upper Lid Crease Construction in Asian Blepharoplasty

William P. D. Chen, MD

**Summary:** The elegance of retrospective analysis of crease construction based on the levels of attachment is that it may be used to correlate a crease's construction method with an outcome of crease depth based on medical record review. It expands on the current knowledge beyond simply describing a crease as being superficial or deep, and is useful for objective analysis of a technique's merit. (*Plast Reconstr Surg Glob Open* 2022;10:e4427; doi: 10.1097/GOX.0000000000004427; Published online 29 July 2022.)

## INTRODUCTION

Double eyelid surgery aims to add a lid crease to an upper lid that is without one. Current approaches tend to favor the use of an external incision as it facilitates direct access to the eyelid skin, orbicularis oculi, tarsus, preaponeurotic fat, and the levator aponeurosis; nevertheless, the original suture methods<sup>1</sup> first used in the early 20th century are still popular in Asia. The history of both approaches is well covered in these references.<sup>1-5</sup> The author published a paper<sup>6</sup> in 2020 pertaining to scoring of abnormal crease height and crease depth findings in revisional cases. Of the two parameters of crease height and depth, Chen<sup>5,6</sup> discussed the importance of accurate placement of crease height in primary cases, while there has not been any substantial paper alluding to the depth level of a crease in any detail beyond Fernandez's<sup>2</sup> original paper in 1960.

## BACKGROUND

The published methods by which the upper lid crease is constructed include the following, as shown in [Figure 1](#):

1. Skin-tarsus-skin attachment (of Putterman<sup>3</sup>; shown as a black dot, exit suture tied on inferior skin surface).
2. Skin→levator aponeurosis→skin attachment (variant of Fernandez<sup>2</sup> for superficial crease, shown as a green dot; exit sutures tied on skin side).
3. Levator to orbicularis (variant methods of Park<sup>4</sup>) as a dark red circle, with one arm of orange hyphenated

exit suture taking inferior orbicularis oculi (represented as passage 1) and the other arm of skin on upper wound edge (passage 2); or of levator→tarsus<sup>3</sup> attachment (second variant of Putterman,<sup>3</sup> not drawn here).

4. Buried suture methods<sup>1</sup> using nondissolvable full-loop sutures to anchor high above the superior tarsal border, looping around levator-Mueller muscle complex and then slanting infero-anteriorly to the orbicularis oculi in front, with suture knot buried beneath skin surface (blue arrows represent trans-lid suture; buried knot lies subcutaneous along upper tarsal border).

Fernandez<sup>2</sup> discussed his two methods of crease construction, with one yielding a superficial crease and the other a deeper crease. He seemed to have favored his superficial crease technique attaching skin-to-aponeurosis, which yielded a dynamic crease in his hands. (A dynamic crease is one which is apparent with the eyelids open, and which fades on downgaze.) The trapezoidal debulking method of Asian blepharoplasty used by Chen<sup>5,6</sup> since 1996 also favored {skin→levator aponeurosis→skin} attachment for crease construction.

## DISCUSSION

It is this author's belief that the depth of crease construction can be further categorized into eight attachment levels, depending on attachment of upper lid skin to various tissue types and sutures used ([Table 1](#)). These levels can be investigated through clinical examination as well as review of operative reports obtained during evaluation of patients with revisional issues.<sup>6</sup> From [Table 1](#) and [Figure 1](#), the four classical methods can be represented as level 4 (black dot), level 3 (green dot), level 5 (red circle), and level 8 (blue

From the Division of Ophthalmology, UCLA School of Medicine, Harbor-UCLA Medical Center, Torrance, Calif.

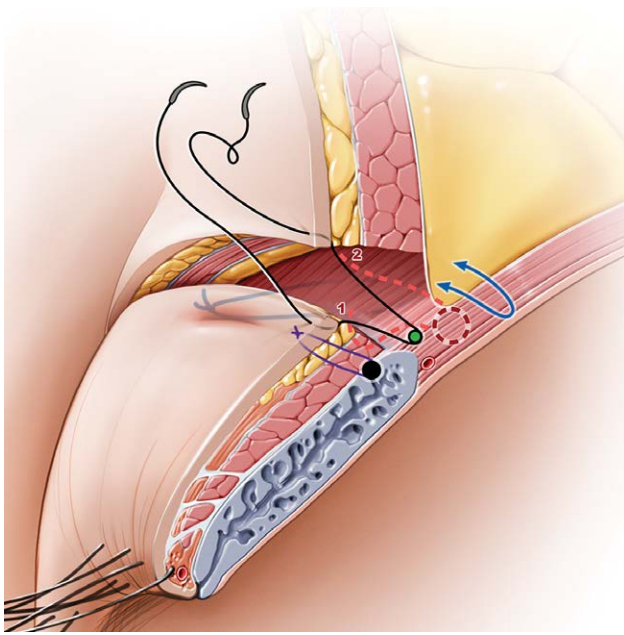
Received for publication February 12, 2022; accepted May 19, 2022.

Copyright © 2022 The Author. Published by Wolters Kluwer Health, Inc. on behalf of The American Society of Plastic Surgeons. This is an open-access article distributed under the terms of the [Creative Commons Attribution-Non Commercial-No Derivatives License 4.0 \(CCBY-NC-ND\)](#), where it is permissible to download and share the work provided it is properly cited. The work cannot be changed in any way or used commercially without permission from the journal.

DOI: 10.1097/GOX.0000000000004427

**Disclosure:** The author has no financial interest to declare in relation to the content of this article.

Related Digital Media are available in the full-text version of the article on [www.PRSGlobalOpen.com](http://www.PRSGlobalOpen.com).



**Fig. 1.** Showing the four main categories of eyelid crease construction. Black dot: skin-tarsus-skin attachment; green dot: skin-levator-skin attachment; red circle: levator-to-orbicularis/tarsus attachment; and blue suture loop: nonincisional buried sutures methods. These correspond to levels 4, 3, 5, and 8.

buried suture loop), respectively. Patients may sometimes complain of a crease being too deep and too obvious when the upper lid is in downgaze. A deep crease is more often associated with attaching skin-to-tarsus as Fernandez<sup>2</sup> previously observed, represented as level 4 here. When dissolvable sutures are buried as in level 5, it enhances crease formation by causing some tissue reaction and fullness in the pretarsal segment.

Level 6 and 7 constructions represent cases where permanently buried, nondissolvable sutures were used in incisional methods, and this can lead to a persistent deep-set crease (Figs. 2 and 3), with some patients complaining of strain, fatigue, or pain in their upper lids and cranial region. (See video [online], which displays Zeiss microscopic-assisted suture removal in a 32-year-old woman who had developed severe eye strain and pain, work disability, with headaches persisting 6 months following

### Takeaways

**Question:** The depth of a constructed upper lid crease is an important factor in evaluating its aesthetic appeal. What are the factors that influence depth of crease construction?

**Findings:** A graduated scale of “eight levels of depth” allows a better understanding of the interplay between tissues engaged, sutures selected, and pitfalls to avoid in upper lid crease construction (Asian double-eyelid surgery).

**Meaning:** One can control the depth of a crease through thoughtful consideration of these factors.

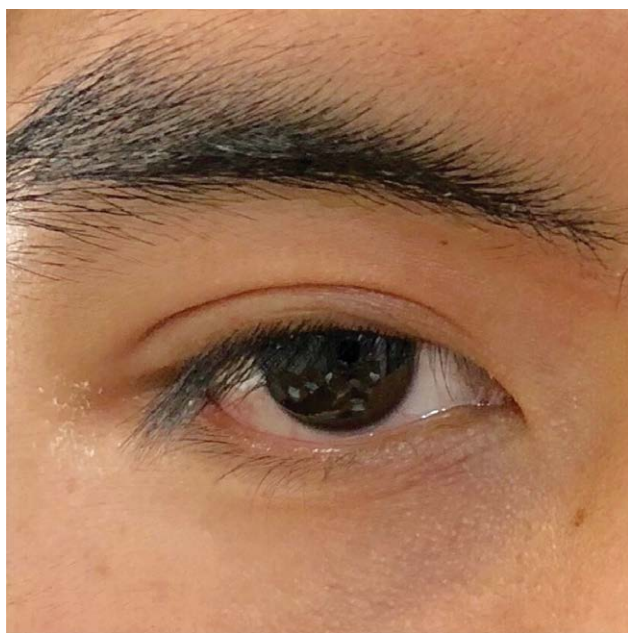upper lid crease procedure via an incisional method. Record showed placement of five buried nonabsorbable 7-0 nylon sutures on each upper eyelid, involving {skin—>tarsus—>skin}. Symptoms were relieved 2 months after removal of all buried sutures.) The application of trans-lid nonabsorbable sutures in buried suture methods encircles the orbicularis oculi and the levator-Mueller muscles within its suture loops, and constitutes the deepest level of attachment, level 8. In the author’s review of medical records, it is associated with a deeper crease, often static, and frequently seen with high crease placement due to the necessity for its needle passages to slant upward to lift the lid fold out of the way. These sutures may erode through the lid tissues resulting in regression of crease formation. Mizuno<sup>8</sup> discussed his management of suture-related complications.

Currently, many papers on Asian blepharoplasty tout their ability to produce a natural, dynamic crease. Some<sup>9-11</sup> used multiple layers of crease fixation. When the flap linkage paper<sup>9</sup> is analyzed,<sup>10</sup> it describes the use of buried nonabsorbable sutures anchoring levator to tarsus (level 6 or 7), then an intermediate pass of {skin—> orbicularis—>lev. aponeurosis—>orbicularis —>skin}. Removable sutures would combine level 1 (skin—>orbic.) plus level 3 (skin—>levator aponeurosis), followed by a third pass of {skin—>aponeurotic flap/bridge tissues} removables, which would be level 3 once again. Zubiri<sup>11</sup> also used buried nonabsorbable sutures to tarsus (level 7) combined to levator aponeurosis and orbicularis (level 5+). With these examples<sup>9,11</sup> of crease construction, one may deduce that such combination will result in crease depth level at least equivalent to the deepest level reached among its component fixation method, and likely

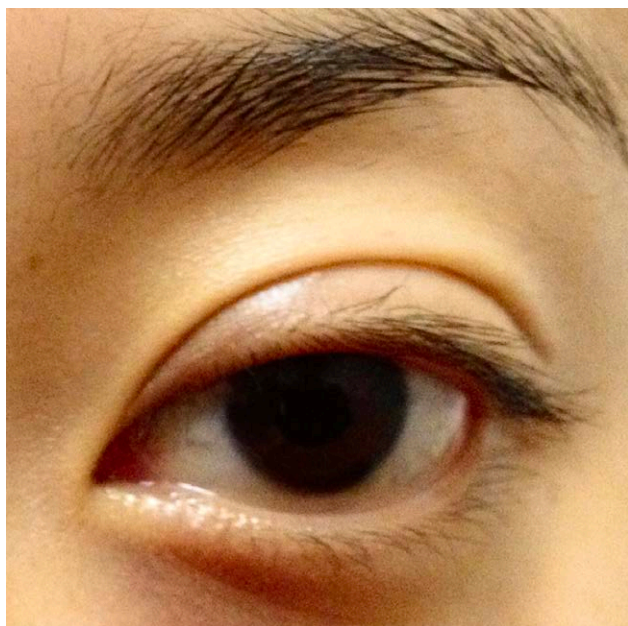
**Table 1. The Levels of Attachment Listed Here in Ascending Numerical Order Correlates Roughly to the Increasing Depth of Crease Construction Using the Route Listed**

Level 0	Skin-to-skin closure (removable stitches, usually does not produce crease)
Level 1	Skin-orbicularis oculi-skin (removable sutures, usually yields shallow or no crease)
Level 2	Skin-orbital septum <sup>7</sup> -skin
Level 3	Skin-levator aponeurosis-skin (removable external sutures, yields dynamic crease)
Level 4	Skin-tarsus-skin (using removable external sutures)
Level 5	Levator aponeurosis-to-inferior orbicularis fixation sutures (when using dissolvable buried sutures)
Level 6	Subcutaneous skin-levator aponeurosis-skin subcutaneous (when using permanent buried knots; static crease)
Level 7	Subcutaneous skin-tarsus-skin (permanent buried knots; static crease)
Level 8	Nonincisional buried suture methods (crease indentation is generated by compression from permanent buried ligatures around orbicularis and levator muscles; no skin incision was made in this variant)

The levels of attachment listed here in ascending order correlate the increasing depth of crease invagination following construction using the technique listed, verified through analysis of operative summaries. For level 3 attachment of skin-Lev. aponeurosis-skin, this dynamic crease corresponds to Fernandez’s original description<sup>2</sup> of what he coined a superficial crease. In level 5, buried absorbable sutures were used. In levels 6–8, permanent buried sutures indicate the use of nonabsorbable sutures, examples being nylon or prolene, irregardless of its caliber. All levels from 3 to 8 typically will produce a consistently noticeable eyelid crease.



**Fig. 2.** Twenty-three-year-old man 2 years after “partial incision anchoring blepharoplasty” with verified history of using three buried 7-0 nylon sutures per eyelid. Crease height of RUL measured 8 mm centrally, and anatomic tarsal height was 7.5 mm. Deep crease is apparent on downgaze. Chief complaints were of eye strain, headaches, and occasional duplication of crease. (The verified record of the use of buried nondissolvable sutures to levator aponeurosis is consistent with level 6 construction.)



**Fig. 3.** Twenty-nine-year-old woman 3 years after external incisional method LUL with nasally joining shape at 8 mm, with prominent static crease exemplifying deeper crease. (The verified record of the use of nondissolvable buried sutures to tarsus is consistent with level 7 construction.)

more. Indeed, this is often corroborated by the authors’ research on revisional effort scoring,<sup>6</sup> where very deep creases with the highest scores (combining crease height, depth, and shape abnormalities) were often seen with operative reports confirming the use of buried nylon sutures fixed to the tarsal plate (level 7 depth of construction) at a crease height higher than the superior tarsal border.

## CONCLUSIONS

By including classical crease construction methods in double eyelid surgery with more recent variants including the use of buried permanent sutures among different tissues, this proposed description (based on review of operative summaries and correlation with suboptimal findings) attempts to provide a framework that allows for a practitioner to quickly assess a technique’s possible impact on eyelid crease depth, and aids in depth control. It has limitation in that the data for this difficult topic are inherently hard to collect in large number, although this author had published a series of 64 cases collected over a period of 13 years.<sup>6</sup> The author hopes that presenting this topic on eyelid crease depth will stimulate further interest, which will lead to improved patient care.

*William P. D. Chen, MD*

Division of Ophthalmology  
UCLA School of Medicine  
Harbor-UCLA Medical Center  
Torrance, CA 90502  
E-mail: [wpdchen@ucla.edu](mailto:wpdchen@ucla.edu)

## REFERENCES

1. Inoue S. The double eyelid operation. *Jpn Rev Clin Ophthalmol.* 1947;27:36.
2. Fernandez LR. Double eyelid operation in the Oriental in Hawaii. *Plast Reconstr Surg Transplant Bull.* 1960;25:257–264.
3. Putterman AM, Urist MJ. Reconstruction of the upper eyelid crease and fold. *Arch Ophthalmol.* 1976;94:1941–1954.
4. Park JI. Orbicularis-levator fixation in double-eyelid operation. *Arch Facial Plast Surg.* 1999;1:90–95.
5. Chen WP. Concept of triangular, trapezoidal, and rectangular debulking of eyelid tissues: application in Asian blepharoplasty. *Plast Reconstr Surg.* 1996;97:212–218.
6. Chen WPD. The eyelid crease height, depth, and shape: a scoring system for revisional Asian blepharoplasty. *Plast Reconstr Surg Global Open.* 2020;8:e2802.
7. Lee JS, Park WJ, Shin MS, et al. Simplified anatomic method of double-eyelid operation: septodermal fixation technique. *Plast Reconstr Surg.* 1997;100:170–178.
8. Mizuno T. Treatment of suture-related complications of buried-suture double-eyelid blepharoplasty in Asians. *Plast Reconstr Surg Global Open.* 2016;4:839.
9. Jin R, Shen Y, Yu W, et al. Tarsal-fixation with aponeurotic flap linkage in blepharoplasty: bridge technique. *Aesthet Surg J.* 2020;40:NP648–NP654.
10. Chen WPD. Commentary on: “tarsal-fixation with aponeurotic flap linkage in blepharoplasty: bridge technique.” *Aesthet Surg J.* 2020;40:NP655–NP656.
11. Zubiri JS. Subdermal placement of sutures in double eyelid surgery. *Aesthet Surg J.* 2013;33:722–732.